

Case Report

Subcutaneous Endometriosis after Cesarean Section: A Case Report

Ardio Rizky Tansil, Tan¹, Irma Savitri², John Rambulangi³

¹ Department of Obstetrics and Gynecology, Faculty of Medicine, Hasanuddin University, Makassar, Indonesia

² Oncology and Gynecology Division, Department of Obstetrics and Gynecology, Faculty of Medicine, Hasanuddin University, Makassar, Indonesia

³ Fertility, Endocrinology and Reproductive Division, Department of Obstetrics and Gynecology, Faculty of Medicine, Hasanuddin University, Makassar, Indonesia

Corresponding Author:

Name: Ardio Rizky Tansil, Tan

Email: dio_tansil@hotmail.com

ARTICLE INFO

Keywords:

Endometriosis;
Subcutaneous Tissue;
Surgical Procedures;
Surgical Wound;
Case Report;

How to cite:

Tan ART., Savitri I.,
Rambulangi J. (2023).
Subcutaneous
Endometriosis after
Cesarean Section: A
Case Report.
Nusantara Medical
Science Journal, 8(1),
19-24

DOI:

[10.20956/nmsj.v8i1.21634](https://doi.org/10.20956/nmsj.v8i1.21634)

ABSTRACT

Introduction and importance: Endometriosis is a condition in which both the stromal tissue and the functional endometrial glands are observed outside the uterine cavity. Endometriosis can be found in pelvic organs and extra-pelvic. Subcutaneous Endometriosis is a condition that may occur after surgical procedures such as cesarean section. **Presentation of case:** We report a 37-year-old female patient who had undergone two cesarean sections and presented with cyclic hypogastric pain and vaginal bleeding 2 years after the surgical procedures. Cyclic bleeding also occurred from the cesarean section scar 1 year ago. Total abdominal hysterectomy, right salpingo-oophorectomy, left salpingectomy and wide excision of the scar were performed. Histopathological examination showed stromal tissue and functional endometrial glands on the subcutaneous part of the skin. After performing wide excision in this patient, GnRH analog was given and the VAS Score reduced to 3. **Discussion:** The incidence of subcutaneous endometriosis can occur months to years after the surgical procedure with an average of about 30 months. Generally, complaints in patients are painful and

*enlarged abdominal masses, especially during menstruation. In this case, preoperatively, the patient has a VAS Score of 10 and a postoperative VAS Score of 3. In establishing the diagnosis of subcutaneous endometriosis, the gold standard is pathological examination. The main management of this subcutaneous endometriosis case is a wide excision procedure by performing excision and providing a minimum clearance of 1 cm. **Conclusions:** The histopathological examination showing glands and endometrial stromal tissue on the excised skin confirmed subcutaneous endometriosis in this patient. The management successfully reduced the pain experienced by the patient.*

Copyright © 2023 NMSJ. All rights reserved.

1. INTRODUCTION

Endometriosis is a condition of functional glands and endometrial stromal tissue that grows outside the uterus. It most often occurs not only in pelvic organs, such as the ovaries and pelvic peritoneum, but also extra pelvic organs, such as lungs, pleura, kidneys, omentum, intestines, and abdominal wall, with an incidence of < 12%.¹⁻⁴ Most cases of endometriosis on the abdominal wall are caused by surgery, such as a cesarean section. Subcutaneous endometriosis is rare with an incidence of 0.03—1.5% in patients with a history of obstetric and gynecological surgery which can occur months to years after the surgical procedure with an average of about 30 months. The chosen action for subcutaneous endometriosis cases is surgical excision with a minimum free margin of 1 cm to prevent recurrence.^{1,2}

2. CASE PRESENTATION

We report a case of a 37-year-old female patient, P2A1, complaining severe lower abdominal pain with VAS Score of 10 and heavy menstrual bleeding at every menstrual cycle for 2 years. She also complained of blood coming out of the wound from the cesarean section for 1 year. The patient underwent cesarean section twice, in 2012 and 2016.

On abdominal examination, an enlarged abdomen was observed with a mass at the hypogastric region measuring 7 x 6 cm, mobile, without tenderness. A mass was also palpable below the umbilicus at the site of the former cesarean section incision. The mass was solid, well-demarcated measuring 2 x 2 cm, immobile, with tenderness over the wound (Fig.1 a). On investigation, ultrasound showed a hypoechoic lesion and irregular edges in the subcutaneous, midline anterior abdominal wall, measuring 2.71 x 2.77 cm suggestive of endometriosis scars (Fig 1 b). There was also an enlarged image, a hypoechoic mass, well-defined, regular surface, measuring +/- 8.5 x 7.25 x 9.1 cm on the posterior wall of myometrium.

The patient was diagnosed with uterine myoma and a suspected scar of endometriosis, leading to elective laparotomy. During the surgery, uterine myomas and right endometriotic cysts were found, so total abdominal hysterectomy, right salpingo-

oophorectomy, left salpingectomy and wide excision of the scar were performed. After the surgery, myoma tissue, left and right tubes, right ovary, and endometriosis scar were sent to Anatomical Pathology (PA) laboratory for examination (Fig 2a). Two weeks later, the definitive diagnosis by histopathological findings were uterine myomas, para tubal cysts, ovarian endometriosis, and subcutaneous endometriosis. From the histopathology result, glands and endometrial stromal tissue on the excised skin were found (Fig 2b). At the next appointment, the patient was given GnRH analog therapy to help reduce endometriosis-related pain.

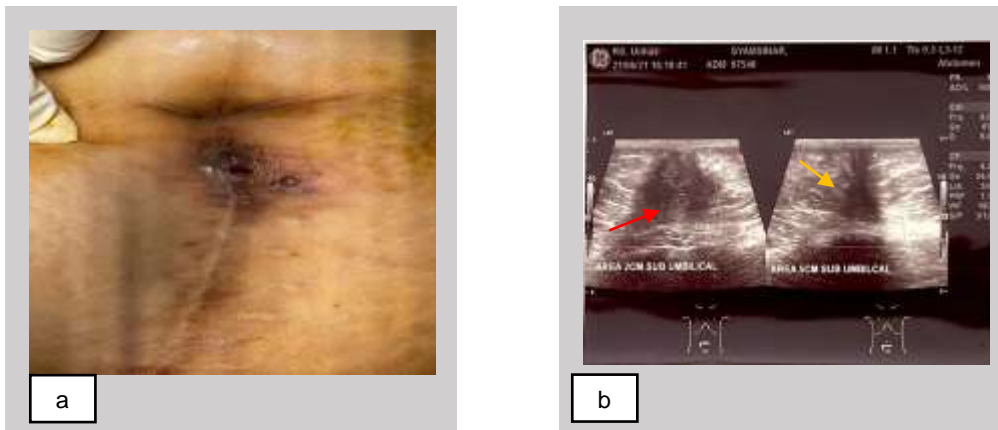


Fig. 1. Abdominal and Ultrasound examination. a) Mass of suspected subcutaneous endometriosis in the post-cesarean section area with blood coming out of the scar during menstruation. (b) The abdominal ultrasound examination showed a hypoechoic lesion (red arrow) and irregular edges (yellow arrow) in the subcutaneous, anterior abdominal wall midline measuring 2.71 x 2.77 cm suggestive of an endometriosis scar.

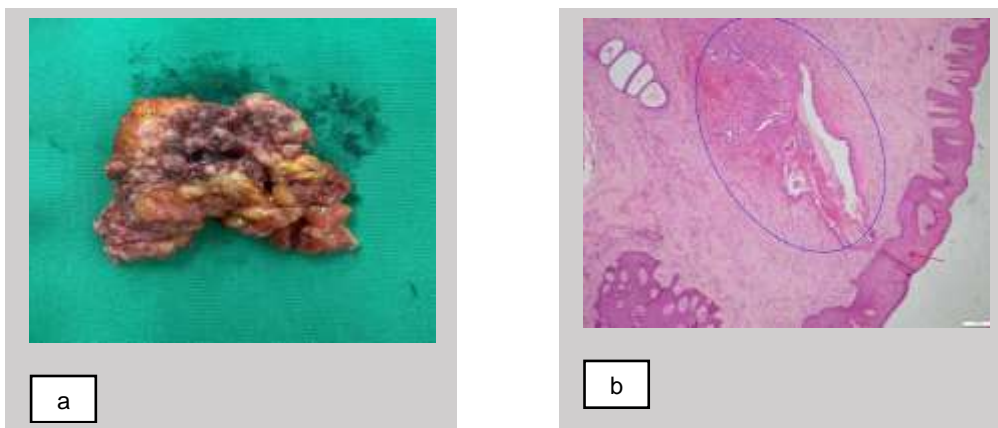


Fig. 2. Post Operative and Histopathological Examination a) Postoperative wide excision of subcutaneous endometriosis, measuring 8 x 4 x 2,5 cm. (b) The tissue lined with the epidermis (red arrow) with connective tissue with endometrial stroma and glands (blue circle) underneath.

3. DISCUSSION

Subcutaneous endometriosis is one type of extra-pelvic endometriosis. It is thought that the pathomechanism of subcutaneous endometriosis is based on the pathophysiological theory of endometriosis, namely the implantation theory. During the cesarean section, iatrogenic implantation occurs at the surgical incision site, where these endometrial cells will proliferate with a supply of nutrients and hormonal effects from the body.^{1,2,4,10}

Research shows that various types of surgery, increase the risk of extra pelvic endometriosis with a cesarean section being the most common cause. The incidence of subcutaneous endometriosis can occur months to years after the surgical procedure with an average of about 30 months, which in the presented case occurred after 24 months after surgery.^{1,2,11}

Complaints in patients are usually in the form of painful and enlarged abdominal mass, especially during menstruation. These complaints are the most common in 70—80% of all patients. Other complaints include dyspareunia or pain that does not follow the menstrual cycle. This complicates the diagnoses of this disease so that a differential diagnosis with lipoma, hematoma, lymphoma, or hernia is often undergone, which we did not find in our patient.^{3,5,12}

In establishing the diagnosis of subcutaneous endometriosis, the gold standard is pathological examination. Ultrasound (USG), CT-Scan, and MRI can be performed to help establish the diagnosis and provide information about the location, size, and volume of the mass, but cannot establish a definite diagnosis of subcutaneous endometriosis.^{1,2,13}

Several intraoperative methods are thought to prevent the incidence of subcutaneous endometriosis. One of them is by irrigation of 0.9% sodium chloride solution on the wound before the surgical wound is closed. This is thought to prevent the implantation of endometrial cells. Another method is by using a different needle in suturing the uterus and abdominal lining.^{2,6,14,15}

The main management of this subcutaneous endometriosis case is a wide excision procedure by performing excision and providing a minimum clearance of 1 cm. Other studies recommend wide excision as the gold standard in the management of this case and medical therapy be given to patients who cannot perform surgery. The recurrence rate of postoperative subcutaneous endometriosis varies, from 4.3 to 7.8% in one to five years.^{1-3,7}

Endometriosis is a chronic disease with the main complaint of pain. Medical therapy with hormonal administration is an alternative to reduce clinical symptoms but cannot eliminate complaints permanently. One treatment option that can be given is a gonadotropin-releasing hormone (GnRH) analog. GnRH analog can be prescribed to reduce endometriosis-associated pain, although evidence is still limited regarding dosage and duration of treatment. Prescribing combined hormonal add-back therapy alongside GnRH agonist should be considered to prevent hypoestrogenic symptoms.⁸⁻¹⁰ In this case, after administration of GnRH analog postoperatively, the VAS Score reduced to 3.

4. CONCLUSION

Subcutaneous endometriosis is extra pelvic endometriosis, which is mainly caused by surgery, one of which is cesarean section. Establishing a definite diagnosis of subcutaneous endometriosis is difficult without any pathological examination. The main management of subcutaneous endometriosis is wide excision with a margin of 1 cm to prevent the recurrence of this disease. Pain reduction could be achieved by administration of GnRH analog.

ETHICAL APPROVAL

Not Applicable.

CONSENT FOR PUBLICATION

All the authors have given consent for the publication of identifiable details, which can include photographs, case history and details within the text to be published in the above Journal.

ACKNOWLEDGMENTS

The authors would like to show appreciation to the Department of Obstetrics and Gynecology, Faculty of Medicine, Hasanuddin University for the assistance provided in this research.

1. Yildirim D, Tatar C, Doğan O, Hut A, Dönmez T, Akıncı M, et al. Post-Cesarean scar endometriosis. *Turkish J Obstet Gynecol*. 2018;15(1):33–8.
2. Ramdani A, Rais K, Rockson O, Serji B, El Harroudi T. Parietal Mass: Two Case Reports of Rare Cesarean Scar Endometriosis. *Cureus*. 2020;12(2):8–13.
3. Khachani I, Filali Adib A, Bezaad R. Cesarean Scar Endometriosis: An Uncommon Surgical Complication on the Rise? Case Report and Literature Review. *Case Rep Obstet Gynecol*. 2017;2017:1–4.
4. Zhang P, Sun Y, Zhang C, Yang Y, Zhang L, Wang N, et al. Cesarean scar endometriosis: Presentation of 198 cases and literature review. *BMC Womens Health*. 2019;19(1):1–6.
5. Nigam A. Subcutaneous endometriosis: A rare cause of deep dyspareunia. *BMJ Case Rep*. 2014;2013–4.
6. Moazeni-Bistgani M. Recommending Different Treatments as Preventive Measures against Incisional Endometrioma. *J Fam Reprod Heal [Internet]*. 2013;7(3):105–8. Available from: <https://www.ncbi.nlm.nih.gov/pubmed/24971111>
7. Djaković I, Vuković A, Bolanča I, Vraneš HS, Kuna K. Abdominal wall endometriosis eleven years after cesarean section: Case report. *Acta Clin Croat*. 2017;56(1):162–5.
8. Laganà AS, Lucia V, Rosa L, Chiara AM, Frangež HB, Bokal EV, et al. Anxiety and depression in patients with endometriosis : impact and management challenges. *Int J Women's Heal*. 2017;9:323–30.
9. Becker C, Bokor A, Heikinheimo O, Horne A, Jansen F, Kiesel L et al. ESHRE guideline: endometriosis. *Human Reproduction Open*. 2022;2022(2).
10. Cherrabi F, Moukit M, Kouach J, Rahali DM, Dehayni M. Cesarean scar endometriosis: a case report. *Int J Reprod Contracept Obstet Gynecol*

- 2018;7:1221-3.
11. Trivikrama HS, Shivakumar, Sajitha AK, Chandni S, Geethanjali R, Lavatt D, et al. Abdominal wall endometriosis in the caesarean section surgical scar-a case report. *Int J Reprod Contracept Obstet Gynecol* 2022;11:2890-4.
 12. Pandey C, Shrestha J, Subedi A, Rana A. Cesarean scar endometriosis – a rare and underestimated complication. *Journal of Chitwan Medical College*.2021;11(38):135-6.
 13. Alnafisah F, Dawa S K, Alalfy S. Skin Endometriosis at the Caesarean Section Scar: A Case Report and Review of the Literature. *Cureus*. 2018;10(1): e2063.
 14. Sumathy S, Mangalakanthi J, Purushothaman K, Sharma D, Remadevi C, Sreedhar S. Symptomatology and surgical perspective of scar endometriosis: a case series of 16 women. *The Journal of Obstetrics and Gynecology of India*. 2017 Jun;67(3):218-23.14.
 15. Ahmed AHS. Cesarean Scar Endometriosis: is Surgical Management Enough?. *M J Gyne*. 2018;3(1): 015.

Conflict of Interest Statement:

The author declares that the case report was conducted in the absence of any commercial or financial relationships that could be construed as a potential conflict of interest.

Copyright © 2023 NMSJ. All rights reserved.